



Electron Microscopical Studies on Lymph node of Pati duck (*Anas platyrhynchos domesticus*) of Assam at Different Stages of Development

A. Deka, J. D. Mahanta and P. Perumal*

Dept. of Anatomy and Histology, AAU-College of Veterinary Science, Khanapara, Guwahati, Assam (781 025), India



Open Access

Corresponding Author

P. Perumal

e-mail: perumalponraj@gmail.com

Citation: Deka et al., 2020. Electron Microscopical Studies on Lymph node of Pati duck (*Anas platyrhynchos domesticus*) of Assam at Different Stages of Development. International Journal of Bio-resource and Stress Management 2020, 11(2), 119-124. [HTTPS://DOI.ORG/10.23910/IJBSM/2020.11.2.2069b](https://doi.org/10.23910/IJBSM/2020.11.2.2069b).

Copyright: © 2020 Deka et al. This is an open access article that permits unrestricted use, distribution and reproduction in any medium after the author(s) and source are credited.

Data Availability Statement: Legal restrictions are imposed on the public sharing of raw data. However, authors have full right to transfer or share the data in raw form upon request subject to either meeting the conditions of the original consents and the original research study. Further, access of data needs to meet whether the user complies with the ethical and legal obligations as data controllers to allow for secondary use of the data outside of the original study.

Funding: The research was conducted with the kind and supports from Institute

Conflict of interests: The authors have declared that no conflict of interest exists.

Abstract

The present investigation was conducted on the histomorphological, histo-chemical and scanning electron microscopical observation on the lymph node of Pati duck of Assam at different stages of development. Structure of the cervical and lumber lymph node of Pati duck revealed the same structure in histomorphological observation. The lymph node was surrounded by a thin connective tissue capsule. The trabeculae which were arisen from the capsule divided the lymph node into number of irregular compartments. The trabeculae became distinct with the advancement of age. The parenchymatus part of these lymph node consisted of inner cortex and outer medulla along the cortical and medullary sinuses. The cortex of lymph node was occupied by numerous follicles with different shape. These lymphoid follicles were surrounded by very thin layer of capsule. The medulla of these lymph node consisted of medullary sinuses and medullary cords. The medullary sinuses were larger compared to the cortical sinuses. The medulla was loosely arranged in week 4th of age of Pati duck whereas in week 16th, 24th and 42nd of age, it became compact. Histochemically, the lymphatic nodule of lymph node showed intense reaction for acid phosphatase at week 42nd of age of Pati duck whereas lymphatic nodule of lymph node showed strong reaction for adenosine tri-phosphatase. In scanning electron microscopy, the lymph node of Pati duck were surrounded by very thin capsule and it contained numerous connective fibers. Medulla of the lymph node was peripherally located whereas cortex was situated centrally. The lymph node contained connective tissue fibers where lymphocytes were attached.

Keywords: Histomorphology, histochemical, electron microscope, lymph node, duck

1. Introduction

Duck husbandry provides an additional source of income to the rural women in Assam. Duck is one of the excellent converters of low quality waste products into high quality animal protein in the form of egg and meat. Duck eggs have great demand in the state of Assam as it has high biological value and considered to be a delicacy food item. The Pati duck population constitutes a major indigenous duck variety in Assam. The lymph nodes play an important role in defense mechanism of Pati duck by secreting IgA. Similar studies were conducted in other poultry species in other organs (Abdalla et al., 2011; Abu Ali et al., 2019; Madkour et al., 2019; Rabbani et al., 2019; Udoumoh et al., 2019). Being an indigenous variety of Assam and very scanty literature is available on the micro-

Article History

RECEIVED in 11th January 2020

RECEIVED in revised form 27th March 2020

ACCEPTED in final form 08th April 2020



anatomical study on the lymph node of Pati duck. Hence, the present study was designed to establish anatomical norms on lymph node of Pati duck of Assam at different stages of development.

2. Materials and Methods

The present studies were conducted on 45 numbers of Pati duck of Assam of male and which were procured from Barpeta district of Assam. The experiment was conducted from 2017 to 2019 (2 years). These ducks were divided into five groups based on the age and each group consisted of 9 numbers of duck. The groups into five types viz., Gr 1: week 1, Gr 2: week 4, Gr 3: week 16, Gr 4: week 24 and Gr 5: week 42 of age. The experimental procedures were conducted at the Department of Anatomy and Histology, College of Veterinary Science, Assam Agricultural University, Khanapara, Guwahati. These ducks were sacrificed with standard slaughter method (Gracy, 1986). The duck of each age group were utilized for histological and micrometrical observation. The samples were collected from lymph node of all age groups of duck. These samples were fixed in 10% neutral buffered formalin solution and were processed as per the standard technique (Luna, 1968). The paraffin blocks were sectioned in Shandon Finesse microtome at 5 μ m thickness and the sections were stained with Mayer's Haematoxylin and Eosin staining technique for cellular details, Van Gieson's method for collagen fibres, Gomori's method for reticular fibres, Hart's method for elastic fibres and Beilschowsky's method for axis cylinder and dendrite. For Histochemical studies, the ducks were sacrificed and immediately collected the lymph nodes (both cervical and lumbar). The samples were then preserved at liquid nitrogen (-196 $^{\circ}$ C). Samples were made into cryosections (-20 $^{\circ}$ C) at 10 μ m thickness and were temporally stored at -22 $^{\circ}$ C. They were than treated for histochemical staining with the following methods:

- Gomori's alkaline phosphatase cobalt method (Singh and Sulochana, 1978)
 - Gomori's method for acid phosphatase (Singh and Sulochana, 1978)
 - Lead method for ATPase (Bancroft, 2008)
 - Gomori's method for non-specific esterase (Bancroft, 2008)
- For ultra-structural studies, the tissue samples were collected from lymph node and were processed as per the technique of Parsons et al. (1991). The samples were cut into small pieces of 2 mm size and were fixed in 2% gluteraldehyde solution for 4 hours at 4 $^{\circ}$ C. The samples were subjected to the following steps:
- Washing: the tissue sections were washed in 0.1M sodium cacodylate buffer- 3 changes of 15 min each at 4 $^{\circ}$ C
 - Post-fixation: the tissues were post-fixed in 1% osmium tetroxide in 0.1M sodium cacodylate buffer at 4 $^{\circ}$ C
 - Washing: the tissue samples were washed in 0.1 M sodium cacodylate buffer- 3 changes of 15 min each at 4 $^{\circ}$ C
 - Dehydration: by ascending grades of acetone, drying: by

tetra methyl saline method (Dey et al., 1989)

e. Mounting: the dry specimens were mounted on aluminium stubs,

f. Coating: gold coating was applied in the tissue samples in a JFC-1100 (Joel) ion sputter coater and the stubs with the tissue samples were loaded in the JMS-35CF (Joel) scanning electron microscope operated at 20KV.

3. Results and Discussion

Histologically, the cervical and lumbar lymph nodes of Pati duck revealed similar structure. The lymph nodes were surrounded by a thin connective tissue capsule. Similar findings were supported by Patki et al. (2009) in Kuttanad duck. The capsule contained collagen, reticular and a few elastic and nerve fibers along with cross section of blood vessels (Figure 1). The trabeculae which were arisen from the capsule divided the lymph node into number of irregular compartments (Figure 2). These findings were in agreement

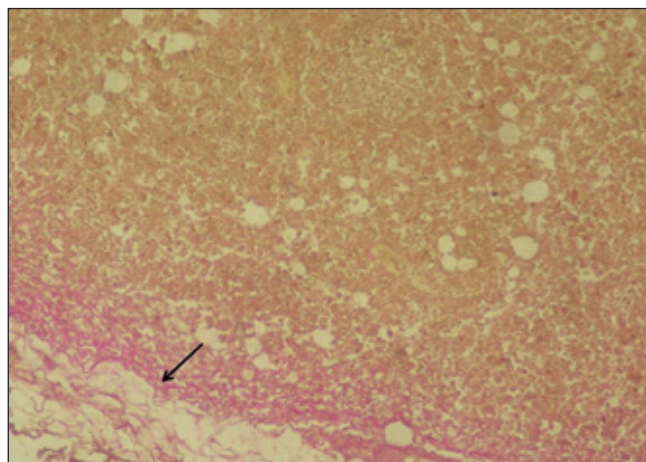


Figure 1: Photomicrograph showing the collagen fibers (black arrow) of capsule of cervical lymph node of 24th week old Pati duck (Van Gieson's method; X10)

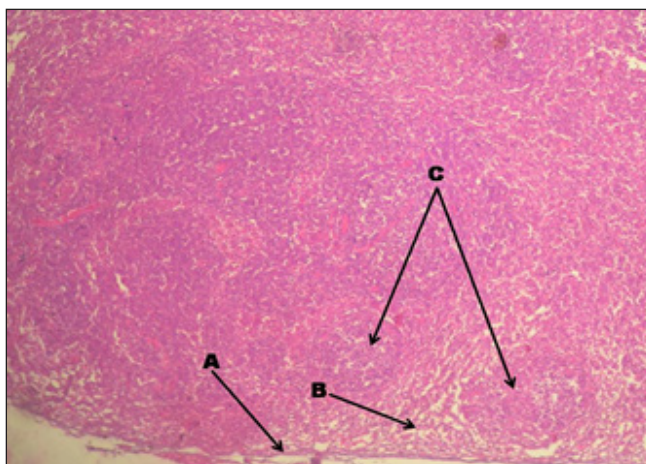


Figure 2: Photomicrograph showing the capsule (a), interfollicular area (b) and lymphoid follicle (c) of cervical lymph node of 42 week old Pati duck (H&E, X10)

with the findings of Lawn and Rose (1981) in duck. The trabeculae became distinct with the advancement of age. This finding was in consonance with the finding of Kumar et al. (2013) in Khaki Campbell duck. It also contained collagen, few elastic and reticular fibers along with nerve fibers (Figure 3). The parenchymatous part of these lymph node consisted

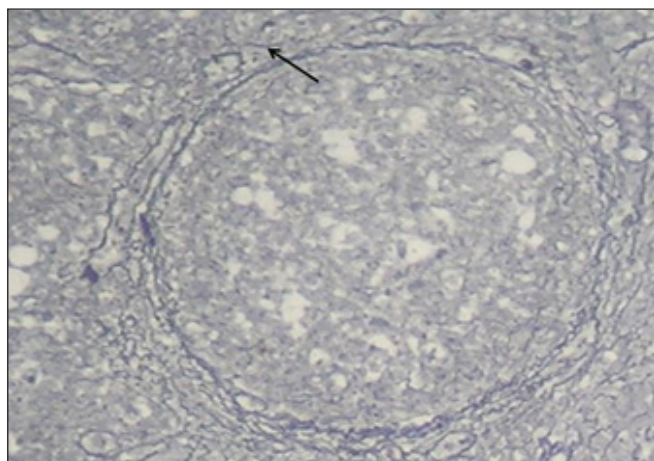


Figure 3: Photomicrograph showing the reticular fibers (black arrow) of cervical lymph node of 16th week old Pati duck (Gomori's method; X40)

of inner cortex and outer medulla along the cortical and medullary sinuses. These findings were in accordance with the findings of Hodges (1974) in duck, Kings and Mclelland (1975) in duck and Nickel et al. (1977) in duck. The cortex and medulla became obscured in all the age groups of duck. The cortex of lymph node was occupied by numerous follicles with different shape (Figure 4). These lymphoid follicles were surrounded by very thin layer of capsule. Similar finding was reported by Hodges (1974) in duck. The capsule was made up of collagen, few elastic, reticular and nerve fibers. The centre of these lymph node contained germinal centre, which was performed by Sugimura et al. (1977) in duck. These lymphoid

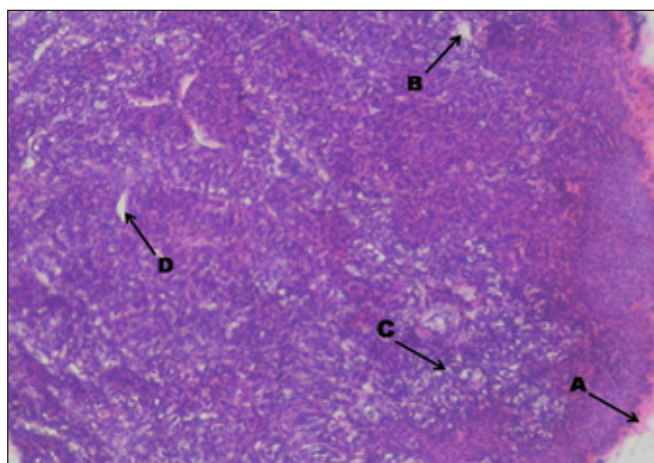


Figure 4: Photomicrograph showing the capsule (A), medullary sinuses (B), loosely arranged medulla (C) and cortical sinuses (D) of 4th week old Pati duck (H & E, X10)

follicles were separated from the capsule and trabeculae by the cortical sinuses. The medulla of these lymph node consisted of medullary sinuses and medullary cords. It also contained collagen, elastic, nerve fibers (Figure 5) and large amounts of reticular fibers (Figure 6). The medullary sinuses were larger compared to the cortical sinuses. The medulla was loosely arranged in week 4th of age of Pati duck (Figure 7) whereas in week 16th, 24th and 42nd of age, it became compact. These findings were in accordance with the findings of Patki et al. (2009) in Kuttanad duck.

Histo-chemically, there was moderate reaction for alkaline phosphatase in lymphatic nodule of lymph node and negative reaction in interfollicular area in all the age groups of Pati duck (Figure 8) in the current study. The capsule showed weak reaction for the enzyme activity in all the age groups of Pati duck.

In the present study, the capsule of the lymph node showed negative reaction in all the age groups of Pati duck. The

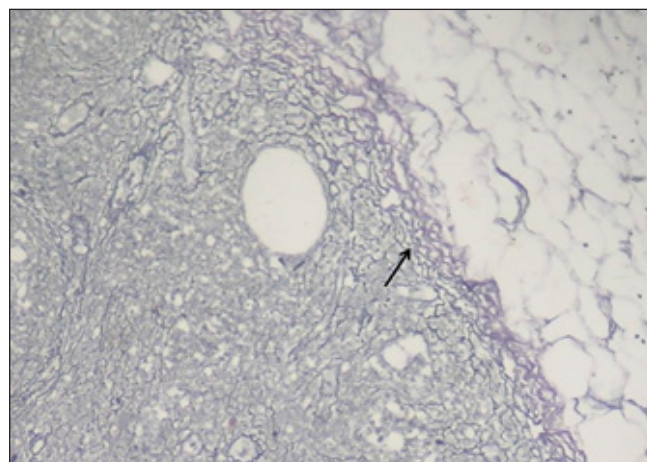


Figure 5: Photomicrograph showing the nerve fibers (black arrow) of capsule of lumbar lymph node of 42th week old Pati duck (Bielschowsky's Method; X10)

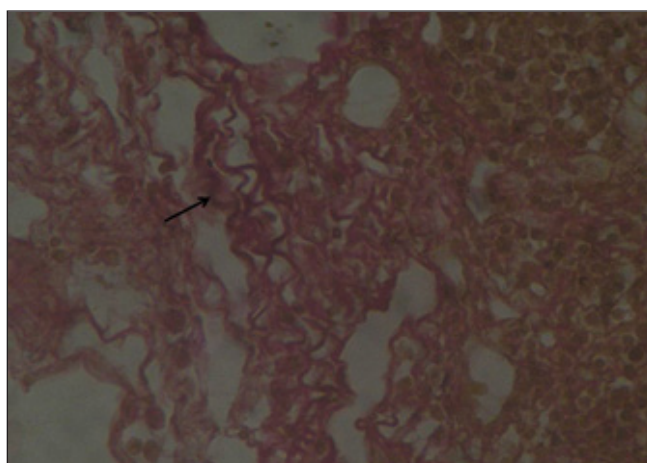


Figure 6: Photomicrograph showing the elastic fibers (black arrow) of capsule of lumbar lymph node of 42th week old Pati duck (Hart's method; X40)

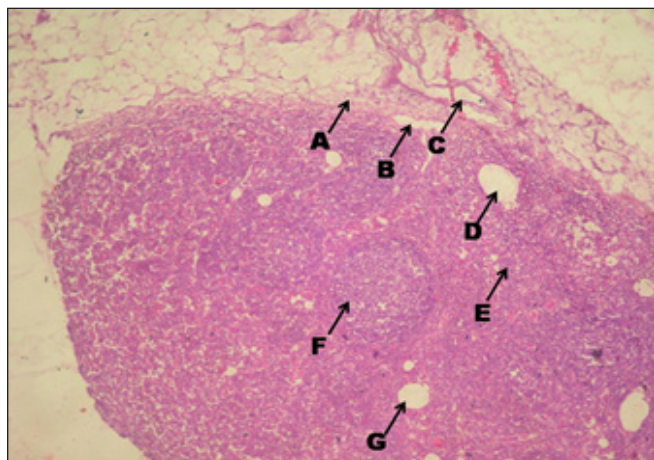


Figure 7: Photomicrograph showing the capsule (a), sub capsular sinuses (b), blood vessels (c), medullary sinuses (d), medullary cord (e), lymphatic nodule (f) and cortical sinuses (g) of lumber lymph node of 24th week old of Pati duck (H &E, X10)




Figure 9: Photomicrograph showing the alkaline phosphatase activity in lymphatic nodule (a), inter follicular area (b) and capsule (c) on 16th week old of Pati duck (Gomori's; X10)




Figure 8: Photomicrograph showing the acid phosphatase activity in lymphatic nodule (a), inter follicular area (b) and capsule (c) on 42th week old of Pati duck (Gomori's; X10)

lymphatic nodule of lymph node showed strong reaction while inter follicular area showed mild reaction of acid phosphatase in all the age groups of duck (Figure 9). However, it could not be compare due to non-availability of literature.

There was a strong reaction in the lymphatic nodule of lymph node and weak reaction in interfollicular area. The capsule showed the weak reaction for the ATPase in all age groups of duck (Figure 10). However, it could not be compare due paucity of literature.

There was a moderate reaction in the lymphatic nodule of lymph node and weak reaction in inter follicular area .The capsule showed the negative reaction for the non-specific esterase in all age groups of duck (Figure 11 and Table 1).

In present investigation, scanning electron microscopic studies of lymph node of Pati duck revealed that it was surrounded by very thin capsule and it contained numerous connective




Figure 10: Photomicrograph showing the adenosine triphosphatase activity in lymphatic nodule (a) and inter follicular area (b) on 4th week old of Pati duck (Lead method; X10)

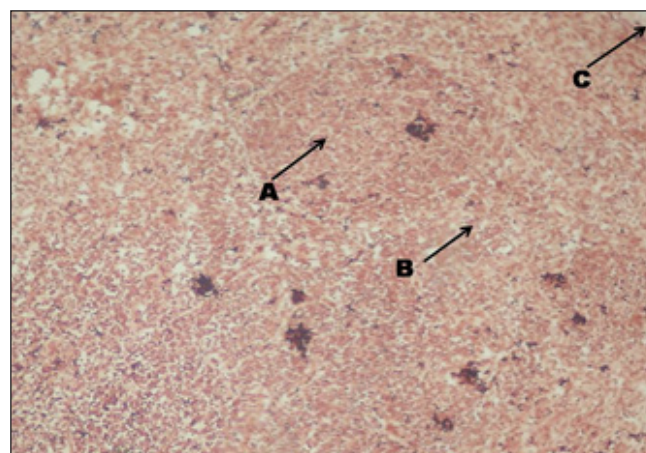


Figure 11: Photomicrograph showing the non-specific esterase activity in lymphatic nodule (a), inter follicular area (b) and capsule (c) on 24th week old of Pati duck (1 Naphthyl acetate method; X10)

fibers. Trabeculae were extended from the capsule towards the centre of the lymph node (Figure12). Similar findings were supported by Fujita et al. (1972) in lymph node of dog. Medulla of the lymph node was peripherally located where as cortex was situated centrally (Figure13). The lymph node

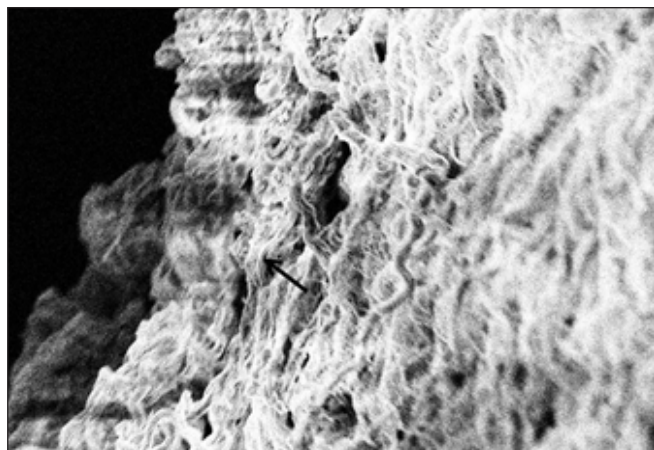


Figure 12: Scanning electron microphotograph showing the connective tissue fibers (black arrow) of capsule of lymph node bar=10 μM, 2.93KX




Figure 13: Scanning electron microphotograph showing the capsule (yellow arrow), medulla (red arrow), trabeculae (white arrow) and cortex (black arrow) of lymph node bar=100 μm, 330X

Table 1: Histochemical characterization of lymph node of Pati duck

| Histoenzymes | Lymphatic nodule | Inter follicular area | Capsule |
|--------------------------|------------------|-----------------------|---------|
| Alkaline Phosphatase | ++ | - | + |
| Acid Phosphatase | +++ | ++ | - |
| Adenosine triphosphatase | +++ | + | + |
| Non specific esterase | ++ | + | - |

Gradation for intensity of histochemical reaction: -= Negative; += Weak; ++ = Moderate; +++ = Strong

contained connective tissue fibers where lymphocytes were attached (Figure 14).




Figure 14: Scanning electron microphotograph showing the connective tissue fibers (black arrow) and lymphocytes (white arrow) of lymph node bar 2 μm, 7.05KX

4. Conclusion

Histologically, cervical and lumber lymph nodes of Pati duck revealed the same structure. The trabeculae of the lymph node became distinct with age advancement. Cortex and medulla became obscured in all age groups. Medulla was loosely arranged in week 4th of age whereas in week 16th, 24th and 42nd of age, it became compact. Histochemically, lymphatic nodule showed intense reaction for acid phosphatase at week 42nd of age whereas lymphatic nodule of lymph node showed strong reaction for adenosine tri-phosphatase.

5. References

- Abdalla, K., Saleh, A., Galil, Y., Mohamed, A., Alsayed, A.A., 2011. Development of the duck tongue: gross, morphometric and scanning electron microscopical study. *Egyptian Journal of Medical Sciences* 32, 401–414.
- Abu Ali, A., Mokhtar, D., Ali, R., Wassif, E., Abdalla, K., 2019. Morphological Characteristics of the Developing Cecum of Japanese Quail (*Coturnix coturnix japonica*). *Microscopy and Microanalysis* 25(4), 1017–1031.
- Bancroft, J.D., 2008. *Theory and Practices of Histological Technique*. Churchill Livingstone, Elsevier Health Sciences. 6th Edn., 267–272.
- Dey, S., Baul, T.S.B., Roy, B., Dey, D., 1989. A new rapid method of air-drying of scanning electron microscopy using tetra methyl saline. *Journal of Microscopy*. Doi.org/10.1111/j.1365-2818.1989.tb02925.
- Fujita, T., Miyoshin, N., Murakami, T., 1972. Scanning electron microscope observation of the dog mesenteric lymph node. *Z. Zellforsch* 133, 147–162.
- Gracy, J.F., 1986. *Bleeding Method of Slaughtering-Slaughter*. Meat Hygiene. 8thedn., 144–145.
- Hodges, R.D., 1974. *The Histology of Fowl*. Editor: Hodges,

- R.D., Academic Press Inc. (London) Ltd., 80–213.
- Kings, A.S., McLelland, J., 1975. Outline of Avian Anatomy. Editors: Kings, A. S. and McLelland, J., Baillier Tindall, London. 6th Edn., 103.
- Kumar, P., Das, P., Paul, S., 2013. Post-natal development of Lymph nodes of Khaki Campbell duck (*Anas platyrhynchos*). Indian Journal of Veterinary Anatomy 25(1), 9–11.
- Lawn, A.M., Rose, M.E., 1981. Presence of a complete endothelial barrier between lymph and lymphoid tissue in the lumbar lymph nodes of the duck (*Anas platyrhynchos*). Research in Veterinary Science 30, 335–342.
- Luna, L.G., 1968. Manuals of histological staining methods of Armed forces institute of Pathology, Ed: Luna, L.G., McGraw Hill Book Co., London. 3rd Edn. 79–207.
- Madkour, F., Abdalla, K., Mohamed, S., 2019. Choana Morphogenesis in Developmental Stages of Muscovy Ducks. SVU-International Journal of Veterinary Sciences 2, 13–26.
- Nickel, R., Schummer, A., Seiferle, E., 1977. Anatomy of the Domestic Birds. Verlag Paul Parey, Berlin, Hamburg, 104.
- Parsons, K.R., Bland, A.P., Hall, G.A., 1991. Follicle associated epithelium of the gut-associated lymphoid tissue of cattle. Veterinary Pathology 28(1), 22–29.
- Patki, H.S., Lucy, K.M., Harshan, K.R., Chungath, J.J., 2009. Postnatal Development of Lymph nodes in Kuttanad Duck (*Anas platyrhynchos domesticus*). IV World Waterfowl Conference, 11-13 November, Thrissur, India, 145–147.
- Rabbani, M.A.G., Das, S.C., Ali, M.A., Md. Hassan, R., Ali, M.Y., 2019. Growth Performance of Pekin Ducks under Full confinement system fed diets with various nutrient concentrations. Asian Journal of Biological Sciences, 12: 717–723.
- Singh, U.B., Sulochana, S., 1978. A Laboratory Manual of Histological and Histochemical Technique. Kothari Medical Publishing House, Bombay, 1st Edn., 50–55.
- Sugimura, M., Hashimoto, Y., Nakanishi, Y.H., 1977. Thymus and Bursa-Dependent Areas in duck lymph nodes. Japanese Journal of Veterinary Research 25, 7–16.
- Udumoh, A.F., Nwaogu, I.C., Igwebuike, U.M., Obidike, I.G., 2019. The morphological characteristics of the Meckel's diverticulum of pre-hatch and post-hatch broiler chicken. Comparative Clinical Pathology 28, 1617–1624.