



# Diagnosis, Incidence and Extent of Adhesions in Buffaloes with Uterine Torsion at Referral Hospital

R. D. Prajapati<sup>1</sup>, P. M. Chauhan<sup>2</sup>✉, A. S. Prajapati<sup>3</sup>, P. T. Sutaria<sup>4</sup> and Y. H. Vaghasiya<sup>1</sup>

<sup>1</sup>Dept. of Veterinary Gynecology & Obstetrics, <sup>2</sup>Dept. of Veterinary Clinics, <sup>4</sup>Dept. of Veterinary Surgery & Radiology, College of Veterinary Science & Animal Husbandry, Kamdhenu University, Sardarkrushinagar, Gujarat (385 506), India

<sup>3</sup>Veterinary Clinical Complex (Medicine), College of Veterinary Science & Animal Husbandry, Kamdhenu University, Anand, Gujarat (388 001), India



Corresponding ✉ [pmchauhan@kamdhenuuni.edu.in](mailto:pmchauhan@kamdhenuuni.edu.in)

ID 0000-0003-3531-6809

## ABSTRACT

The present study was conducted to determine the incidence and extent of uterine adhesions following uterine torsion in Mehsana buffaloes. A total of 109 uterine torsion-affected buffaloes were recorded for treatment during the January, 2020 to December, 2022, and they are included in the present work. All the buffaloes were scanned by per-rectal, trans-abdominal ultrasonography and grossly inspection of the uterus during the caesarean section for the presence of adhesions and its nature of extensiveness to the uterus. The uterine adhesions through ultrasonography were predicted by the presence of fibrin bands and absent of anechoic fluid between the omentum and uterine serosa layer. Grossly, the extent of the uterine adhesions was classified as either localized or widespread type flimsy to dense in nature during the caesarean operation. The intra-operative in-situ detorsion was achieved in buffaloes with flimsy type uterine adhesions. The overall incidence of adhesions was recorded to be 29.36%. Among them, the incidence of localized type was observed in 21 buffaloes (65.62%) and widespread variety in 11 buffaloes (34.38%), either flimsy or dense. The majority of adhesions were found between the uterus and the inner omental layer. It is concluded that the incidence of uterine adhesions in uterine torsion-affected buffaloes was reported to be 29.36% using different techniques to identify the localized to widespread uterine adhesions. Further, ultrasonography can be helpful in the prediction and early detection of uterine adhesion in buffaloes with uterine torsion, which helps in better obstetrical management.

**KEYWORDS:** Buffalo, incidence, ultrasonography, uterine adhesions, uterine torsion

**Citation (VANCOUVER):** Prajapati et al., Diagnosis, Incidence and Extent of Adhesions in Buffaloes with Uterine Torsion at Referral Hospital. *International Journal of Bio-resource and Stress Management*, 2024; 15(7), 01-06. [HTTPS://DOI.ORG/10.23910/1.2024.5352](https://doi.org/10.23910/1.2024.5352).

**Copyright:** © 2024 Prajapati et al. This is an open access article that permits unrestricted use, distribution and reproduction in any medium after the author(s) and source are credited.

**Data Availability Statement:** Legal restrictions are imposed on the public sharing of raw data. However, authors have full right to transfer or share the data in raw form upon request subject to either meeting the conditions of the original consents and the original research study. Further, access of data needs to meet whether the user complies with the ethical and legal obligations as data controllers to allow for secondary use of the data outside of the original study.

**Conflict of interests:** The authors have declared that no conflict of interest exists.

RECEIVED on 05<sup>th</sup> April 2024

RECEIVED in revised form on 20<sup>th</sup> June 2024

ACCEPTED in final form on 04<sup>th</sup> July 2024

PUBLISHED on 11<sup>th</sup> July 2024

## 1. INTRODUCTION

Adhesions are a mysterious condition that forms abnormal fibrous connections between single or two anatomically different surfaces of organs. Usually, the abdominal organs cannot adhere to each other due to the unique characteristics of the peritoneum and serosal layers of various organs (Awonuga et al., 2011). The peritoneum layer secretes the peritoneal fluid, which lubricates the abdominal tissues and has an excellent fibrinolytic property. Moreover, the serosal layer of the abdominal organs has a soothing property that helps move the particular organ within the cavity and prevents adhesions. Mostly, adhesions can occur due to alterations in the properties of the serosal layer of the organ due to ischemia caused by twisting, trauma, and surgical intervention (Kumar et al., 2019; Chauhan, 2018).

In buffaloes, uterine torsion is a common obstetrical condition in which the pregnant uterus rotates with variable degrees, side and site to its longitudinal axis, which leads to inflammation, oedema, ischemia, and necrosis of the uterus depending on its duration and degree. These pathological changes severely altered the normal physiological functions of both uterine serosa and peritoneum, promoting the formation of adhesions. The formation of uterine adhesions has been a grave concern in uterine torsion-affected buffaloes, more with prolonged duration and higher degrees of uterine torsion, as earlier reported by Dhindsa et al. (2008) and Chauhan et al. (2018). In delayed cases of uterine torsion, the uterus and peritoneum, after becoming ischemia, lose their spontaneous ability to lyse fibrin and also inhibit fibrinolysis, thus leading to fibrin deposition and adhesion formation (Buckman et al., 1976). Suppose repair is delayed, leading to a decrease in fibrinolysis activities in peritoneal fluid and start the fibroblast growth on day 3, and angiogenesis on day 5 results in adhesion formation (Koninckx et al., 2016). The low availability of peritoneal fluid also caused the loss of its lubricant properties and free motility of internal visceral organs into the cavity. Also, the inflammatory reactions in the uterine wall, tissue anoxia, and serosal injury all lead to adhesions of the uterus with the adjoining abdominal viscera or omentum (Ghuman, 2010). The early detection and diagnosis of uterine adhesion and its severity by different techniques in uterine torsion-affected buffaloes help in better obstetrical management in terms of either proceeding to the rolling of the dam or caesarean section (Chauhan, 2018; Sutaria et al., 2018). Therefore, the present study was planned to determine the incidence and extent of uterine adhesions following uterine torsion in Mehsana buffaloes at the Veterinary Clinical Complex, Deesa.

## 2. MATERIALS AND METHODS

A total of 109 Mehsana buffaloes suffered from uterine torsion and were brought for treatment at the clinical

complex, Deesa, from the January, 2020 to December, 2022 were included in the present study. All the buffaloes were examined for the presence of uterine adhesion by per-rectal, trans-abdominal ultrasonography and the time of caesarean section besides its clinical attributes like side, site, degree, and duration of torsion. On per-rectal examination, the uterine adhesions were diagnosed based on the palpate the free uterine greater curvature, which was tense and friction feel due to the wrapping of the omentum around the uterus and the inability of the hand to move or restricted insertion on either side of the uterus (Noakes et al., 2001; Smereczynski et al., 2012; Chauhan et al., 2019).

The trans-abdominal ultrasonography was performed in 71 uterine torsion-affected buffaloes by using a C60/5-2 MHz convex array transducer prior to obstetrical operations (Sonosite, Titan, USA). The transabdominal ultrasound scanning was started from the right lower flank, followed by the ventral abdomen, inguinal and left lower flank region after preparation of the site. The uterine adhesions were predicted or diagnosed based on the movement of visceral organs (rumen and intestine) concurrent to the uterine wall, beside the anechoic to the hypoechoic area seen between the oedematized uterine wall and omentum (Figure 1a), presence of floating fibrous bands on the serosal surface of the uterine wall (Figure 1b) and no anechoic area seen between the uterine wall and omentum (Figure 1c). Uterine oedema was more pronounced in uterine adhesion-affected buffaloes than in non-uterine adhesion-affected buffaloes. However, the severity of the adhesions may depend on the duration of torsion. Sometimes, it is challenging to diagnose uterine adhesions by ultrasonography and, later, confirm their extensiveness during caesarean section.

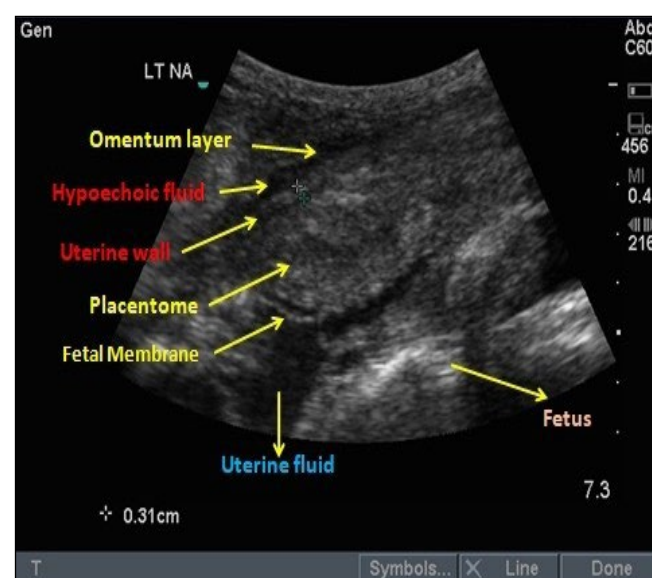


Figure 1a: Presence of fluid between oedematized uterine wall and omentum

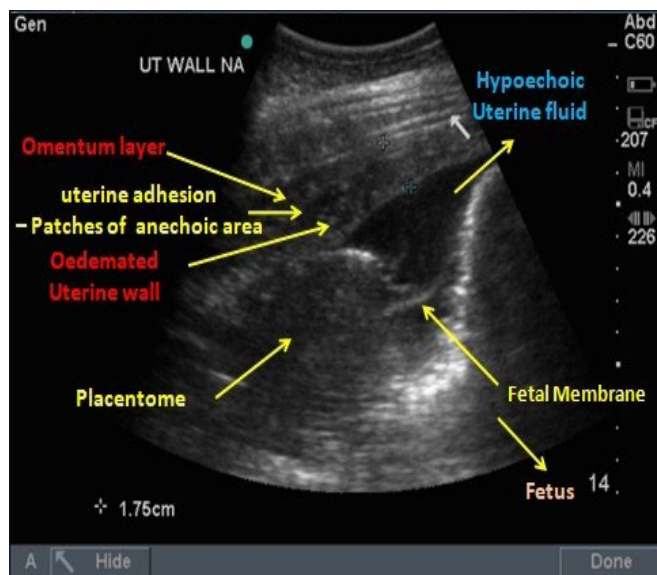


Figure 1b: Presence of fibrous band on the uterine wall

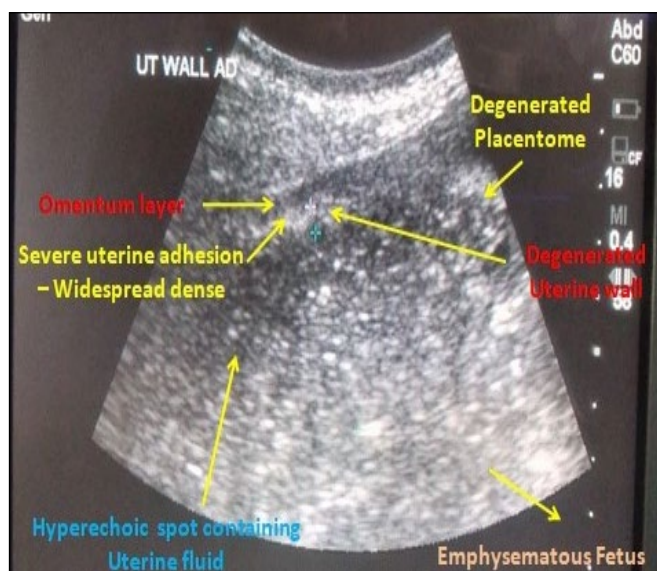

Figure 1c: Absence of fluid between the uterine wall and omentum

Figure 1: Sonograms indicating the presence or absence of uterine adhesions

The caesarean section was performed on 44 buffaloes who suffered from non-reducible uterine torsion as per the method described by Roberts (1971). During the caesarean section, the uterine wall and other visceral organs were grossly examined for the presence or absence of uterine adhesion besides its extensiveness and severity. Out of 44 buffaloes, 32 buffaloes suffered from uterine adhesion, while 12 buffaloes without uterine adhesions (Figure 2a). The extensiveness of uterine adhesions (n=32) was noted and categorized as localized (flimsy or dense; Figure 2b), and widespread (flimsy or dense; Figure 2c) as per described by Fredericks et al. (1986) and Chauhan (2018).

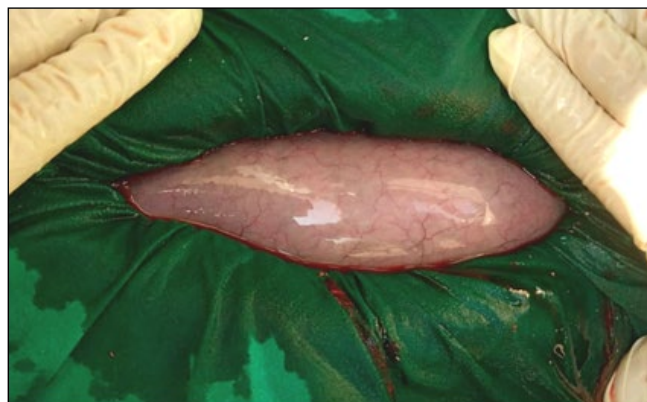

Figure 2a: Uterine non-adhesion

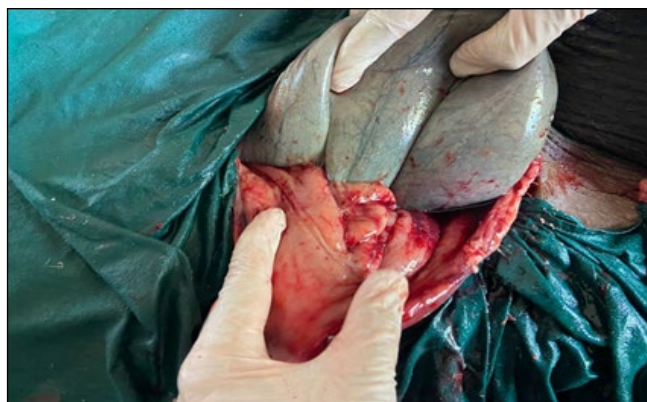

Figure 2b: Localized, flimsy-type uterine adhesions

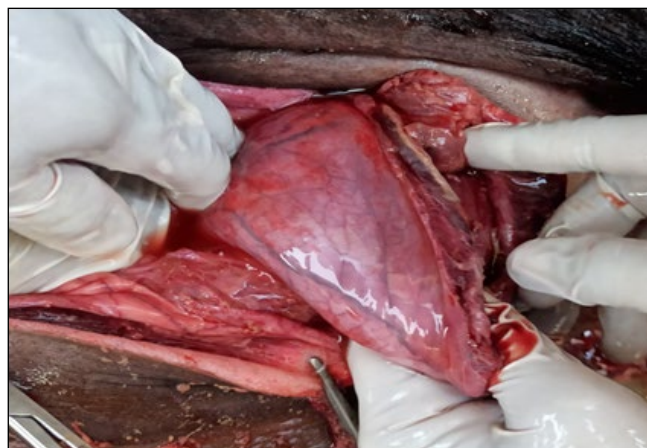

Figure 2c: Widespread dense-type uterine adhesions

Figure 2: Gross examination of uterine adhesions during caesarean operation in buffaloes with uterine torsion

The prediction and diagnostic efficacy of different techniques, as well as the incidence and extensiveness of uterine adhesion from uterine torsion-affected buffaloes, were observed from January, 2020 to December, 2022. The overall and year-wise incidence of uterine adhesions (%) among the uterine torsion-affected buffaloes was calculated by the formula, total number of uterine adhesions affected buffaloes divided by total number of uterine torsion-affected



buffaloes multiplied by 100. The data generated was analyzed to see the significance by using the chi-square test.

### 3. RESULTS AND DISCUSSION

#### 3.1. Prediction and diagnostic efficacy of different techniques

The uterine adhesions were predicted in 25 (22.93%) and 27 (38.02%) uterine torsion-affected buffaloes by per-rectal and ultrasonographic examination, respectively. At the same time, gross inspection of uterine adhesions was diagnosed in 32 (72.72%) out of 44 non-reducible uterine torsion-affected Mehsana buffaloes during the caesarean operation (Table 1). Among them, five buffaloes were directly operated without ultrasonographic examinations due to their critical general health, and localized flimsy and dense to widespread dense type uterine adhesions were recorded. Meanwhile, 24 buffaloes were predicted to have uterine adhesions by ultrasonographic examination, which was confirmed later during a caesarean operation. Controversely, on ultrasonographic examinations, one buffalo was expected to have widespread dense-type uterine adhesions, but at the time of the caesarean operation, it did not show uterine adhesions. Further, two cases were predicted with non-adhesions of the uterus with surrounding viscera; widespread flimsy and dense uterine adhesions were found. This false positive result of the ultrasonographic examination might be due to the accumulation of fluid between the two layers

of the omentum and the tight wrapping of the omentum around the twisted uterus. A significant difference was found between buffaloes with and without uterine adhesions in all techniques. Similarly, a slightly higher number of buffaloes were diagnosed to suffer from uterine adhesions at the time of caesarean section as compared to trans-abdominal ultrasonographic examination.

#### 3.2. Overall incidence of uterine adhesions

The overall incidence of uterine adhesions among the uterine torsion-affected buffaloes was recorded to be 29.36% (32/109). A highly significant ( $p < 0.0001$ ) difference was found between buffaloes with and without uterine adhesions. The present findings are in close agreement with the earlier findings of Chauhan et al. (2019a), who reported 33.33% intra-operative uterine adhesions in the same breed. A higher percentage of uterine adhesions has been reported earlier (Luthra and Khar, 1999; Chauhan et al., 2018; Sutaria et al., 2022), whereas a lower percentage of uterine adhesion was also observed by Bhatol (2007) and Matharu and Prabhakar (2001) then the present findings. Chauhan et al. (2019b) recorded a much higher percentage (83.33%) of the development of uterine adhesions following caesarean section.

The highest incidence of uterine adhesion was recorded in the year 2022 (35.90%; 14/39), followed by 2021 (32.43%, 12/37), and the lowest recorded in 2020 (18.18%; 6/33). At the same time, corresponding values for uterine torsion-affected buffaloes without uterine adhesions were 64.10% (25/39), 67.57% (25/27), and 81.82% (27/33), respectively. There was a significant difference between adhesions and non-adhesion following uterine torsion in the years 2020 ( $p < 0.0003$ ) and 2021 ( $p < 0.03$ ), whereas non-significant variation ( $p < 0.0782$ ) was observed in the year 2022 (Table 2). The incidence of uterine adhesions year-wise gradually increased from 18.18% in 2020 to 35.90% in 2022. The increasing trend of uterine adhesions might be attributed to the frequent use of trans-abdominal ultrasonography for diagnosis, besides the delayed case reporting at the clinics by owners.

Table 1: Prediction and diagnostic efficacy of uterine adhesions by different techniques

Sl. No.	Techniques (n)	Uterine adhesions	Uterine non-adhesions	Significance
1.	Per-rectal technique (n=109)	25 (22.93%)	84 (77.06%)	$\chi^2 df_1 = 31.94$ $p < 0.0001$ ; S
2.	Ultrasonographic technique (n=71)	27 (38.02%)	44 (61.98%)	$\chi^2 df_1 = 4.070$ $p = 0.0436$ ; S
3.	Caesarean operation (n=44)	32 (72.72%)	12 (27.27%)	$\chi^2 df_1 = 9.091$ $p = 0.0026$ ; S

Table 2: Overall and year-wise incidence of uterine adhesions following uterine torsion

Sr. No.	Year	Incidence			Significance
		Total No. of Buffaloes affected with uterine torsion (n)	Buffaloes without uterine adhesions n (%)	Buffaloes with uterine adhesions n (%)	
1.	2020	33	27 (81.82)	6 (18.18)	$\chi^2 df_1 = 13.36$ ; $p = 0.0003$ S
2.	2021	37	25 (67.57)	12 (32.43)	$\chi^2 df_1 = 4.57$ ; $p = 0.03$ S
3.	2022	39	25 (64.10)	14 (35.90)	$\chi^2 df_1 = 3.102$ ; $p = 0.0782$ NS
Overall incidence (Percent)		109	77 (70.64)	32 (29.36)	$\chi^2 df_1 = 18.578$ ; $p < 0.0001$ S

The pre-existing uterine adhesions were higher in cows who had previously operated on caesarean section (Hoeben et al., 1997; Mijiten et al., 1997). The uterine torsion-affected buffaloes were free from utero-omental adhesions after a 12-16 h duration of illness with more than 180–360° uterine torsion (Ghuman et al., 1997). The development of utero-omental adhesions increased as the duration of torsion increased from 24–72 h (Prabhakar et al., 1997; Luthara and Khar, 1999). However, significantly higher percentages of development of uterine adhesions (42.85%) were recorded with a duration of illness exceeding > 72 h (Chauhan et al., 2019a). The incidence of uterine adhesion formation was higher in buffaloes suffering with the right side, pre-cervical, > 180 degrees, and duration >48 h (Chauhan et al., 2018; Chauhan et al., 2019a). This variation in the development of utero-omental adhesions following uterine torsions might be accredited to the higher degree and prolonged duration of the torsion, which leads to the inflammatory and ischemic changes into the peritoneum and uterine musculature, causing to loss their spontaneous fibrinolytic property, leads to the formation of adhesions with adjoining abdominal viscera or omentum (Buckman et al., 1976; Ghuman, 2010; Chauhan et al., 2018).

### 3.3. Extent of uterine adhesions

Out of the total of 32 buffaloes with uterine adhesions, at the time of recorded caesarean operation, the incidence of localized and widespread type uterine adhesions, either flimsy or dense, was recorded to be 65.62% (21/32) and 34.37% (11/32) in buffaloes suffering from uterine torsion, respectively (Table 3). A non-significant association was seen between the percentage of localized and widespread uterine adhesions in uterine torsion-affected buffaloes.

Table 3: Extent of uterine adhesions in uterine torsion affected Mehsana buffaloes (n=32)

S1. Case No.		No. of cases (n=32)	Incidence (%)	Significance
1.	Localized (Flimsy or dense)	21	65.62	$\chi^2 df_1=3.125$ $p=0.0771$ NS
2.	Widespread (Flimsy or dense)	11	34.37	

Similar to the present findings, Sutaria et al. (2018) diagnosed 37.50% of diffuse-type uterine adhesions through trans-abdominal ultrasonography. Whereas, in contrast to the current findings, Chauhan et al. (2019a) and Sutaria et al. (2022) recorded 57.90% and 59.25% widespread and 42.11% and 40.74% localized types of uterine adhesions diagnosed intra-operatively during caesarean section and ultrasonography in uterine torsion

affected buffaloes, respectively. Further, the prevention of post-operative uterine adhesions was effectively studied by Chauhan et al. (2019b), and diagnosed severe type of uterine adhesions in 83.33% of buffaloes in a non-treated group following caesarean section. The extensiveness of the uterine adhesions depends on the various clinical attributes of uterine torsions, including site, side, degree, and duration (Chauhan et al., 2019a). The variation in the formation and development of uterine adhesions in the present study might be attributed to the prolonged duration and high degree of uterine torsion, which leads to the infiltration of fibroblast growth and angiogenesis within 3–5 days of uterine torsion resulting in the formation of uterine adhesions due to the reduce the fibrinolytic activity and ischemic changes into the uterus (Koninchx et al., 2016).

## 4. CONCLUSION

Around 29.36% of uterine torsion-affected Mehsana buffaloes suffered from uterine adhesions, the majority localized flimsy or dense type (67.62%) in nature. Further, the uterine adhesions can be effectively diagnosed through trans-abdominal ultrasonographic scanning at different site.

## 5. ACKNOWLEDGEMENT

The authors acknowledge the Principal of the College of Veterinary Science & Animal Husbandry, Kamdhenu University, Sardarkrushinagar, for providing the necessary facilities for the present study.

## 6. REFERENCES

- Bhatol, G.J., 2007. Studies in uterine torsion in buffaloes. M. V. Sc. Thesis, Submitted to Department of Animal Reproduction, Gynaecology and Obstetrics, CVSc, SDAU, Sardarkrushinagar.
- Buckman Jr, R.F., Buckman, P.D., Hufnagel, H.V., Gervin, A.S., 1976. A physiologic basis for the adhesion-free healing of deperitonealized surfaces. The Journal of Surgical Research 21(2), 67–76.
- Chauhan, P.M., 2018. Clinico-biochemical attributes and prevention of post-operative adhesions in mehsana buffaloes affected with uterine torsion. Ph. D. Thesis submitted to S.D.A.U, Sardarkrushinagar, Dantiwada, Gujarat, India.
- Chauhan, P.M., Sharma, V.K., Nakhashi, H.C., Sutaria, T.V., 2019b. Prevention and evaluation of post-caesarean uterine adhesions in torsion affected Mehsana buffaloes. Ruminant Science 8(1), 35–38.
- Chauhan, P.M., Sharma, V.K., Sutaria, T.V., 2019a. Clinico-obstetrical attributes and development of adhesions in Mehsana buffaloes suffering from uterine torsion. Haryana Veterinarian 58, 80–83.
- Chauhan, P.M., Sutaria, T.V., Sharma, V.K., Suthar,

- B.N., Nakhashi, H.C., Patel, J.G., 2018. Studies on uterine adhesion and haemogram of torsion affected Mehsana buffaloes. In: 34<sup>th</sup> International symposium on Productivity Enhancement through Augmenting Reproductive Efficiency of Livestock for Sustainable Rural Economy, AAU, Anand, pp 219.
- Fredericks, C.M., Kotry, I., Holtz, G., Askalani, A.H., Serour, G.I., 1986. Adhesion prevention in the rabbit with sodium carboxymethylcellulose solutions. *American Journal of Obstetrics and Gynecology* 155(3), 667–670.
- Ghuman, S.P.S., 2010. Uterine torsion in bovines: a review. *Indian Journal of Animal Sciences* 80(4), 289–305.
- Ghuman, S.P.S., Sharma, R.D., Prabhakar, S., Nanda, A.S., 1997. Plasma cortisol and blood glucose milieu as an index of stress in buffaloes with uterine torsion. *Indian Journal of Animal Reproduction* 18(1), 83–84.
- Hoeben, D., Mijten, P., de Kruif, A., 1997. Factors influencing complications during caesarean section on the standing cow. *Veterinary Quarterly* 19(2), 88–92.
- Koninckx, P.R., Gomel, V., Ussia, A., Adamyan, L., 2016. Role of the peritoneal cavity in the prevention of postoperative adhesions, pain, and fatigue. *Fertility and Sterility* 106(5), 998–1010.
- Luthra, R.A., Khar, S.K., 1999. Survival rate following different regimes of treatment in cases of uterine torsion in buffaloes. *Indian Veterinary Journal* 76(5), 399–402.
- Matharu, S.S., Prabhakar, S., 2001. Clinical observations and success of treatment of uterine torsion in buffaloes. *Indian Journal of Animal Reproduction* 22(1), 45–48.
- Mijten, P., Van den Bogaard, A.E., Hazen, M.J., de Kruif, A., 1997. Bacterial contamination of fetal fluids at the time of cesarean section in the cow. *Theriogenology* 48(3), 513–521.
- Noakes, D.E., Parkinson, T.J., England, G.C.W., 2001. Maternal dystocia: causes and treatment (9<sup>th</sup> Edn.). In: *Arthur's Veterinary Reproduction and Obstetrics*. Saunders, New York, 229–244.
- Prabhakar, S., Dhaliwal, G.S., Sharma, R.D., Nanda, A.S., 1997. Success of treatment and dam survival in bovines with precervical uterine torsion. *Indian Journal of Animal Reproduction* 18(2), 121–123.
- Roberts, S.J., 1971. *Veterinary obstetrics and genital diseases* (2<sup>nd</sup> Edn.). CBS publishers and distributors, New Delhi.
- Smereczynski, A., Starzynska, T., Kolaczyk, K., Bojko, S., Galdynska, M., Bernatowicz, E., Walecka, A., 2012. Intra-abdominal adhesions in ultrasound. Part I: The visceroperitoneal borderline, anatomy and the method of examination. *Journal of Ultrasonography* 12(51), 472–478.
- Sutaria, T.V., Chaudhari, R.K., Sutaria, P.T., 2022. Ultrasonographic diagnosis of adhesions, quantification of uterine wall and managerial perspectives of uterine torsion in buffaloes. *Reproduction in Domestic Animals* 57(12), 1505–1519.
- Sutaria, T.V., Chaudhari, R.K., Sutaria, P.T., Patel, M.P., Chaudhari, C.F., 2018. Ultrasonographic diagnosis of adhesions and managerial perspectives of uterine torsion in buffaloes. In: 34<sup>th</sup> International symposium on Productivity Enhancement through Augmenting Reproductive Efficiency of Livestock for Sustainable Rural Economy, AAU, Anand, pp 198.